

REVIEW ARTICLE

Lumbar microdiscectomy and microendoscopic discectomy

RON I. RIESENBURGER & CARLOS A. DAVID

Lahey Clinic Department of Neurosurgery, Burlington, Massachusetts, USA

Abstract

Lumbar microdiscectomy, which relies on the operating microscope for visualization, was first described in the late 1970s. This operation is considered the gold standard procedure for patients who require surgery for symptomatic lumbar disc herniation causing radiculopathy that has not improved with conservative measures. A new approach to the management of symptomatic lumbar disc herniation, microendoscopic discectomy, was introduced in 1997. This operation utilizes a tubular retractor system and a microendoscope for visualization rather than the operating microscope. As it is a new procedure, long-term outcomes have not yet been established for this operation. However, recent literature suggests that microendoscopic discectomy may be as effective as the traditional lumbar microdiscectomy in relieving radiculopathy. This article describes the operative techniques and outcomes reported in the literature for both lumbar microdiscectomy and microendoscopic discectomy.

Key words: *Discectomy, microendoscopic, herniated disc, lumbar*

Brief history

In 1934 William Mixter and Joseph Barr published the first detailed description of a lumbar discectomy (1). Their operation was modified over the next few decades, but the application of microsurgical techniques was not described until the late 1970s. In 1977 and 1978, Yasargil (2), Caspar (3) and Williams (4) all described microsurgical techniques for discectomy using the operating microscope. Slight modifications to these techniques have been made over the last thirty years, but the operation has not changed much since described by these three neurosurgeons. Lumbar microdiscectomy is considered the treatment of choice for patients who require surgery for symptomatic lumbar disc herniation causing radiculopathy that has not improved with conservative measures.

The most recent advancement in lumbar discectomy is the introduction of the microendoscope. Building upon Schreiber and Suezawa (5), and Mayer and Brock's initial efforts (6), Foley and Smith (7) introduced microendoscopic discectomy in 1997. This more recent technique that utilizes a microendoscope instead of the operating microscope

for visualization has not yet been widely adopted. However, the procedure is becoming more popular as recent studies have demonstrated post-operative results that are comparable to the results reported after lumbar microdiscectomy.

Lumbar microdiscectomy – description of the procedure

The patient is placed in the prone position after intubation. Lower extremity sequential compression devices are applied for deep vein thrombosis prophylaxis. The patient is positioned with the abdomen hanging freely in order to avoid increased intraabdominal pressure. This prevents epidural venous congestion and troublesome bleeding which can obscure the surgeon's operative field (8). The arms, which are placed abducted on armboards, must be well padded to avoid brachial plexus or ulnar nerve injury. Pressure on the eyes must be avoided as a prolonged increase in intraocular pressure can cause blindness (9).

The level to be operated on is first approximated by palpating the sacrum and using the iliac crests to

roughly estimate the L4-L5 interspace. A spinal needle is then placed into an interspace and an x-ray is taken to identify the spinal level. The incision is then made with a knife over the correct interspace. Monopolar electrocautery is used to divide the subcutaneous tissues. This exposes the lumbodorsal fascia. The fascia is incised in a slightly arcuate manner in order to preserve the interspinous ligaments. The paraspinous muscles are then detached from the spinous processes, laminae, and the medial facet. Care must be taken to maintain the dissection in the subperiosteal plane to avoid bleeding and undue trauma to the muscles. This is done with a sharp periosteal elevator and monopolar electrocautery. A sponge can then be guided over the bony surfaces with the periosteal elevator to clean any residual muscle left on the lamina. Remaining muscle obscuring the ligamentum flavum can be removed with a Leksell or pituitary rongeur. The inferior aspect of the superior lamina, the medial facet, and the superior aspect of the inferior lamina are all thinned using a high-speed drill and/or Leksell and Kerrison rongeurs.

The next goal of the operation is to remove the ligamentum flavum and gain access to the epidural space, which can be done in one of three ways:

- The ligamentum flavum can be detached from the undersurface of the rostral lamina and then be removed in a superior to inferior manner.
- It can be detached from the rostral end of the inferior lamina and be removed in an inferior to superior manner.
- The fibers can be cut and further separated with a small dissector such as a Penfield 4 in a longitudinal fashion and subsequently be removed with Kerrison punches.

All three methods will reveal the epidural space. At this point in time, the dura of the thecal sac and the nerve root that is compressed by the herniated disc are identified. Occasionally epidural fat will obscure these structures. This fat should be removed with a pituitary rongeurs or shrunk back with bipolar forceps. The nerve root can be gently mobilized medially to reveal the disc space and the overlying epidural veins. The veins must be coagulated with bipolar forceps and cut with fine microscissors. Blunt nerve hooks, down-angled curettes, and Penfield dissectors can be used to mobilize free disc fragments that can then be removed with pituitary rongeurs. With the nerve root protected medially by a nerve root retractor or a blunt suction tip, the posterior longitudinal ligament is inspected. If it is healed over and no further disc fragments are encountered, the operation is completed. When an

opening in the posterior longitudinal ligament is encountered, the opening is incised and disc material from the disc space can be extracted using the instruments previously mentioned. It is important to put the pituitary instrument in the disc space no further than approximately 2.5 cm to avoid penetrating the anterior longitudinal ligament. Traction or penetrating this ligament can lead to catastrophic injury to the great vessels.

The nerve root and its foramen are gently palpated with microdissectors to assure the surgeon that the nerve root is adequately decompressed. After hemostasis is achieved, the fascia, subcutaneous tissue, and skin are closed in standard fashion. Steri-Strips are then applied to the skin.

Microendoscopic lumbar discectomy – description of procedure

The same positioning principles are applied as described in the previous section. An operative bed must be used that will allow intraoperative lateral fluoroscopy, which is required for this procedure. The METRx system (Medtronic Sofamor Danek, Memphis, TN, USA), which has a tubular retractor system, is used. An incision is made approximately 1.5 cm off the midline, using a spinal needle for localization as in the previous section. A k-wire is advanced through the fascia and between the fibers of the paraspinous muscles under fluoroscopic guidance toward the junction of the rostral lamina and the medial facet. This wire must not plunge into the interlaminar space in order to avoid dural tear or nerve root injury (10). A small initial dilator is placed over the K-wire and is swept in a medial-lateral direction to sweep the muscle off the laminae. Sequentially larger dilators are placed over the first dilator. Once the final tubular retractor is placed over the largest dilator, a lateral fluoroscopic image is repeated to ensure that the surgeon is working at the correct spinal level. The microendoscope is then attached to the tubular retractor. The video cart that displays the image from the microendoscope must be placed across from the surgeon so that he/she can work in a comfortable fashion. The remaining bone removal, ligamentum flavectomy, identification of the nerve root, and discectomy are all performed in the same manner as described in the previous section on lumbar microdiscectomy but with endoscopic visualization rather than microscopic.

Comparison of the two procedures

There are really only two differences between the two procedures: The manner in which the

paraspinous muscles are handled, and the vehicle used for visualization. In the lumbar microdiscectomy, the paraspinous muscles are detached from the spinous processes and lamina and retracted laterally. In the microendoscopic procedure, the paraspinous muscle is not detached from the spinous processes. Instead, the k-wire, dilators, and tubular retractor are all advanced between the fibers of the paraspinous muscles. Proponents of this technique believe that this “muscle splitting” approach causes less trauma to the muscle and therefore leads to less incisional pain during the post-operative period.

The other difference is the use of the operating microscope versus the use of the microendoscope for visualization. Both systems provide excellent illumination and magnification.

As microendoscopic discectomy was just introduced in the late 1990s, there are many neurosurgeons that are not familiar with the procedure. Nowitzke, a neurosurgeon with considerable experience with lumbar microdiscectomy, published a paper describing his experience in acquiring the ability to perform microendoscopic discectomy (11). He felt he became proficient with the procedure after observing one case, studying cadavers for two days, and then performing thirty actual operations.

Results

Possibly the most statistically rigorous paper detailing outcomes after lumbar microdiscectomy was published in 2002 by Asch et al. (12). In this prospective study of 212 patients, eighty percent experienced relief of leg pain with a mean follow-up of 2 years. This result is similar to many others published in the literature (13,14).

To date there is no literature that has rigorously analyzed outcomes after lumbar microendoscopic discectomy with two-year follow-up. In one recent study of 28 patients with a herniated lumbar disc, half of the patients underwent microdiscectomy and half underwent microendoscopic discectomy (15). At mean follow-up of one year there was no difference in pain outcomes between the two groups. In addition, the authors point out that the patients in the microendoscopic discectomy group required 8.8 doses of postoperative oral analgesics versus 12 doses in the microdiscectomy group (a 26% difference). Again, proponents of the microendoscopic discectomy theorize that the muscle-splitting approach may lead to less post-operative pain, which appears to be supported by this small study. Ideally, a large prospective, randomized study with long-term follow-up needs to be done to compare outcomes between the two procedures. If the

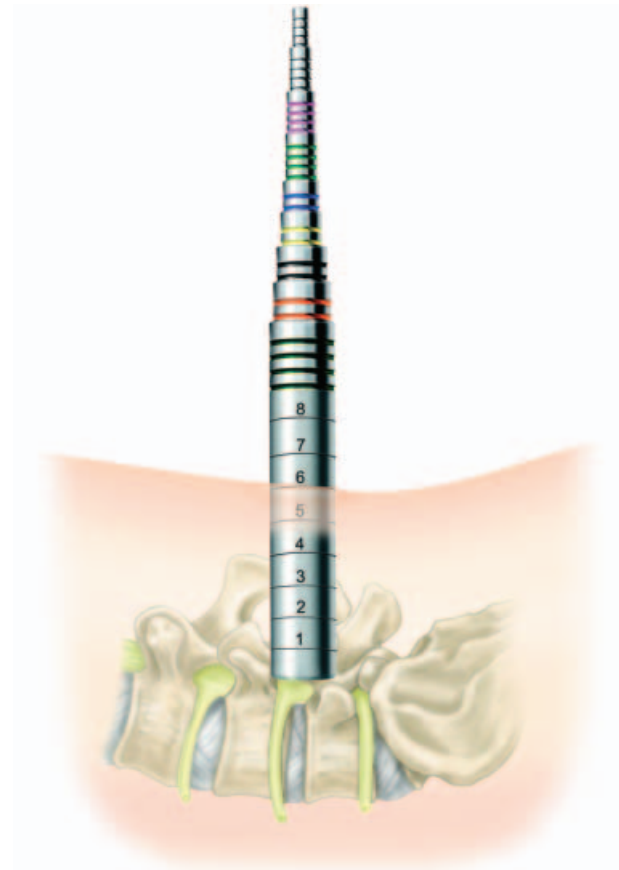


Figure 1. Lateral picture showing METRx sequential tubular dilators aimed at the L4-L5 disc. (The METRx System incorporates technology developed by Gary K. Michelson, M.D.)

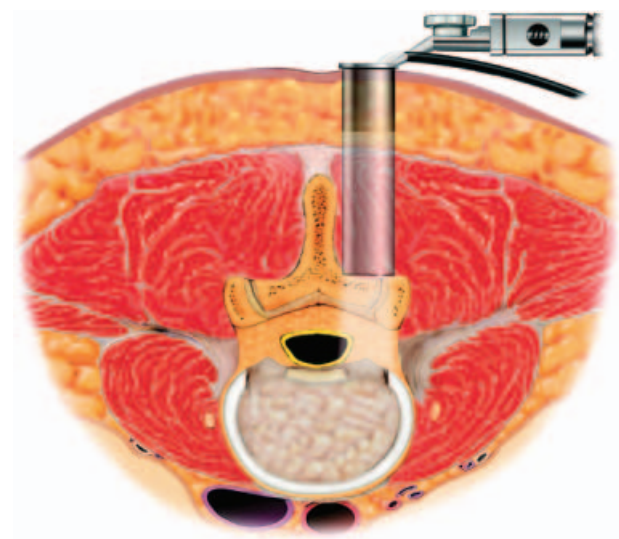


Figure 2. Axial picture showing the METRx tubular retractor aimed at the L4-L5 disc. (The METRx System incorporates technology developed by Gary K. Michelson, M.D.)

microendoscopic approach does turn out to have a marginally smaller post-operative oral analgesic requirement, then it could become the gold standard procedure. However, proponents of the microdiscectomy procedure might consider this small difference insignificant.

References

1. Mixer WJ, Barr JS. Rupture of intervertebral disc with involvement of the spinal canal. *N Engl J Med*. 1934;211: 210–5.
2. Yasargil MG. Microsurgical operation for herniated disc, in: Wullenweber R, Brock M, Hamer J, Klinger M, Spoerri O, editors. *Advances in Neurosurgery*. Berlin: Springer-Verlag; 1977. p. 81.
3. Caspar W. A new surgical procedure for lumbar disc herniation causing less tissue damage through a microsurgical approach, in: Wullenweber R, Brock M, Hamer J, Klinger M, Spoerri O, editors. *Advances in Neurosurgery*. Berlin: Springer-Verlag; 1977. pp. 74–7.
4. Williams RW. Microlumbar discectomy: A conservative approach to the virgin herniated lumbar disc. *Spine* 3:175–182, 1978.
5. Schreiber A, Suezawa Y. Transdiscoscopic percutaneous nucleotomy in disc herniation. *Orthop Rev*. 1986;15: 35–8.
6. Mayer HM, Brock M. Percutaneous endoscopic discectomy: Surgical technique and preliminary results compared to microsurgical discectomy. *J Neurosurg*. 1993;78:216–25.
7. Foley KT, Smith MM. Microendoscopic discectomy. *Tech Neurosurg*. 1997;3:301–7.
8. Caspar W, Campbell B, Barbier DD, et al. The Caspar microsurgical discectomy and comparison with a conventional standard lumbar disc procedure. *Neurosurgery*. 1991;28:78–87.
9. Katz DM, Trobe JD, Cornblath WT, et al. Ischemic optic neuropathy after lumbar spine surgery. *Arch Ophthalmol*. 1994;112:925–31.
10. Perez-Cruet MJ, Foley KT, Isaacs RE, et al. Microendoscopic lumbar discectomy: Technical note. *Neurosurgery*, 2002;51 (suppl 2):129–36.
11. Nowtizke AM. Assessment of the learning curve for lumbar microendoscopic discectomy. *Neurosurgery*. 2005;56: 755–62.
12. Asch HL, Lewis PJ, Moreland DB, et al. Prospective multiple outcomes study of outpatient lumbar microdiscectomy: should 75 to 80% success rates be the norm? *J Neurosurg*. 2002;96(Spine 1):34–44.
13. Abramovitz JN, Neff SR. Lumbar disc surgery: results of the Prospective Lumbar Discectomy Study of the Joint Section on Disorders of the Spine and Peripheral Nerves of the American Association of Neurological Surgeons and the Congress of Neurological Surgeons. *Neurosurgery*. 1991;29: 301–8.
14. Quigley MR, Bost J, Maroon JC, et al. Outcome after microdiscectomy: results of a prospective single institutional study. *Surg Neurol*. 1998;49:263–8.
15. Schivas C, Tsiridis E, Saksena J. Microendoscopic discectomy compared with standard microsurgical discectomy for treatment of uncontained or large contained disc herniations. *Neurosurgery*. 2005;57(ONS Suppl 3):ONS 357–ONS 360.